

## Inflammatory Myofibroblastic Tumour of Urinary Bladder

Sandip Pramanik<sup>1</sup>, Dilip Kumar Pal<sup>2</sup>

<sup>1</sup>Post Doctoral Trainee, Dept. of Urology, Institute of Post Graduate Medical Education & Research, Kolkata-700020, India

<sup>2</sup>Professor & Head, Dept. of Urology, Institute of Post Graduate Medical Education & Research, Kolkata-700020, India

### \*Corresponding author

Dilip Kumar Pal

Email: [drdkpal@yahoo.co.in](mailto:drdkpal@yahoo.co.in)

**Abstract:** Inflammatory myofibroblastic tumour (IMT) is a rare tumour of urinary bladder, which is of unknown neoplastic potential, characterized by spindle cell proliferation with characteristic fibroinflammatory and pseudosarcomatous appearance. We present a case of inflammatory myofibroblastic tumour of a 30 year old lady with successful outcome by transurethral resection.

**Keywords:** Inflammatory myofibroblastic tumour, Anaplastic Lymphoma Kinase, Urinary Bladder

### INTRODUCTION

An inflammatory myofibroblastic tumour (IMT) is very rare in the genitourinary tract. It can arise from a wide variety of anatomic locations [1]. IMT rarely occurs in the urinary bladder, and IMTs of the urinary bladder are difficult to distinguish from other malignant spindle cell proliferations [2-4]. Essential criteria for the diagnosis of IMT are spindle myoepithelial cell proliferation and lymphocytic infiltrate. It is difficult to distinguish these tumours from other malignant spindle cell proliferations. The detection of Anaplastic Lymphoma Kinase (ALK) protein by Immunohistochemistry is useful in distinguishing IMT from spindle cell malignancies in the urinary bladder.

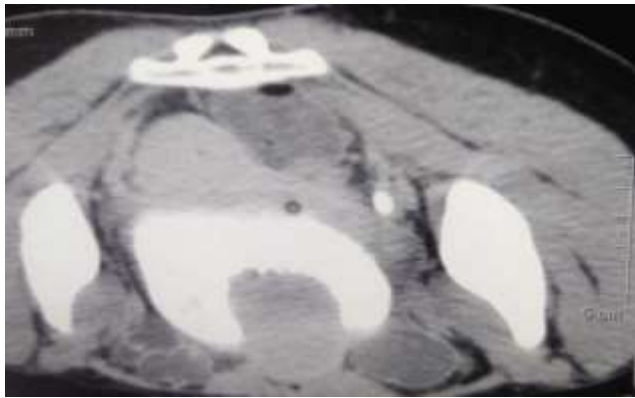
### CASE REPORT

A 30 year old woman presented to our emergency with history of haematuria for 3 weeks. Prior to that haematuria she had burning micturition for last 3 months. She had history of passage of amorphous clots. There was no history of clot colic, graveluria, voiding or storage LUTS (Lower Urinary Tract Symptoms). She had no other comorbidities. On physical examination, she had severe pallor. Per abdominal examination was unremarkable. Her Haemoglobin level was 4.7 gm/dl on admission. USG Whole Abdomen revealed Solid Polypoidal Space Occupying Lesion (34mm×26mm) in anterior wall (? Papilloma). Cystopanendoscopy (CPE) was done for clot evacuation and documentation of urinary bladder tumour. A large anterior wall growth which bleeds on touch was noticed after clot evacuation. CECT Whole Abdomen with CT Urography documented no lymph node enlargement in abdomen and pelvis as well as no metastasis in abdominal and pelvic organs. It also

documented large anterior urinary bladder wall growth (Figures 1, 2).

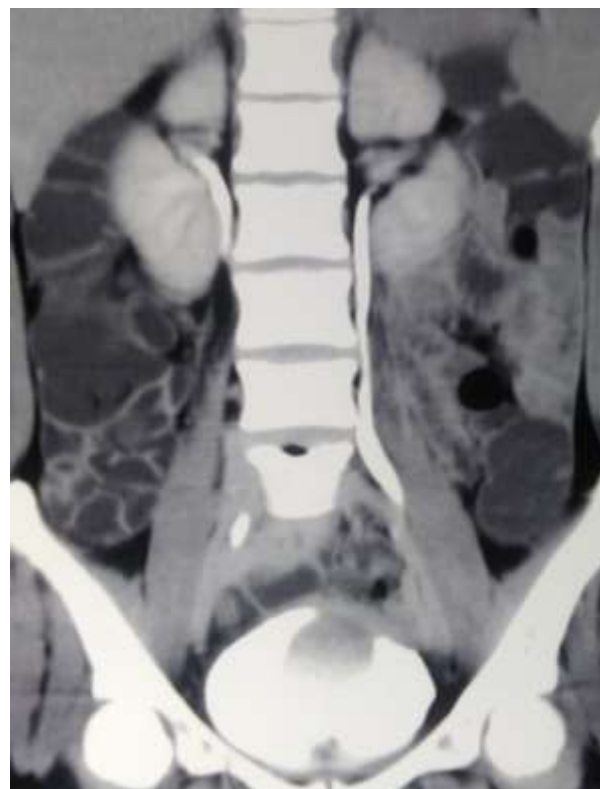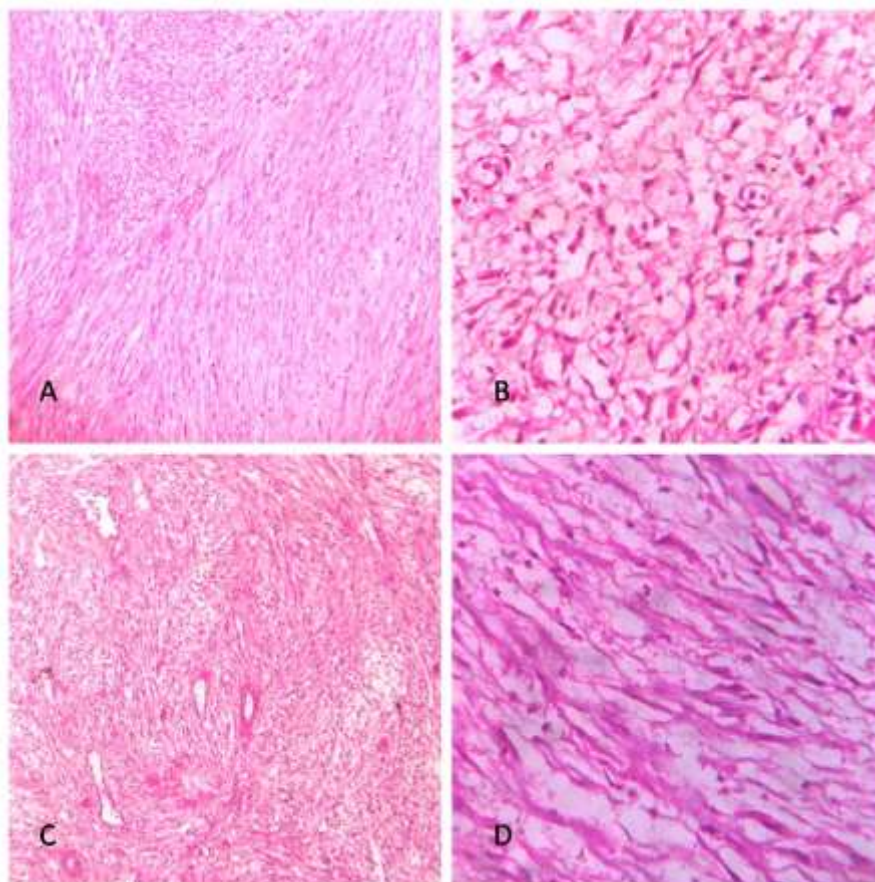


Fig-1: Coronal view of anterior wall urinary bladder tumour in CECT



**Fig-2: Irregular Filling defect in the anterior wall of urinary bladder**

Patient was planned for TURBT after improvement of general condition. TURBT was done under spinal anaesthesia and complete clearance achieved. Gross Examination revealed multiple greyish white tissue pieces. Histopathological examination of resected tumour specimen was suggestive of Inflammatory Myofibroblastic Tumour (Figure 3-a,b,c,d).



**Fig-3: Photomicrograph showing inflammatory myofibroblastic tumour [A: Spindle cells arranged in storiform pattern (H&EX100) B: Prominent lymphoplasmacytic infiltrate (H&EX400) C: Fascicles of spindle cells with myxoid areas and thin walled blood vessels (H &EX100) D: Individual cells have oval nuclei with fine chromatin, and bipolar eosinophilic cytoplasm(H&EX400)]**

## DISCUSSION

Inflammatory myofibroblastic tumour (IMT) of the urinary bladder was first reported in 1980 [2] and is characterized by atypical spindle cell proliferation and inflammatory cell infiltrates primarily involving lymphocytes and plasma cells. IMTs resemble malignant spindle cell tumours both morphologically and immunologically, and the differential pathological diagnosis is difficult [2-4].

The male-to-female ratio ranges from 2:1 to 3:1 [3-5]. The first large series of 38 cases was comprised of patients aged 2.5 months to 87 years [3]. Among the 38 cases, the mean age of patients was 38 years for pseudotumour (age range, 15-74 years), 65 years for postoperative spindle cell nodule, 51 years for sarcoma, and 76 years for carcinoma [3]. Anaplastic Lymphoma Kinase (ALK), originally identified as a protein overexpression in anaplastic large-cell lymphoma,

was overexpressed in a substantial proportion of IMTs [4,6-9]. ALK overexpression detected by immunohistochemistry in up to 87.5% of the IMTs is useful for the differentiation of IMTs from other malignant spindle cell lesions [4,6-9] In our case, the definitive pathological diagnosis was made by ALK immunopositivity in the biopsy specimen. ALK-positive inflammatory myofibroblastic tumours of the urinary bladder have a female predilection, occur more frequently in younger patients, and have different immunohistochemical staining patterns when compared with ALK-negative inflammatory myofibroblastic tumours [10].

In most reported cases of IMTs of the urinary bladder, surgical resections, including transurethral resection and partial and radical cystectomy, were performed; the complete surgical resection in previous cases was important to avoid local recurrence [3,4,11]. There is a report of unresectable IMTs successfully treated with steroids and non-steroidal anti-inflammatory drugs [12]. A case of IMTs of the urinary bladder with malignant transformation and multiple metastases is also reported [13]. It is also reported that regardless of its ALK status, inflammatory myofibroblastic tumours of the urinary bladder have a good prognosis after surgical resection [10]. No recurrence of the disease has been detected till one year of follow up.

## REFERENCES

1. Coffin CM, Watterson J, Priest JR, Dehner LP. Extrapulmonary inflammatory myofibroblastic tumour (inflammatory pseudotumour). A clinicopathologic and immunohistochemical study of 84 cases. *Am J Surg Pathol.* 1995; 19: 859-872.
2. Roth JA. Reactive pseudosarcomatous response in urinary bladder. *Urology.* 1980; 16: 635-637.
3. Iczkowski KA, Shanks JH, Gadaleanu V, Cheng L, Jones EC, Neumann R, Nascimento AG, Bostwick DG. Inflammatory pseudotumour and sarcoma of urinary bladder: differential diagnosis and outcome in thirty-eight spindle cell neoplasms. *Mod Pathol.* 2001; 14: 1043-1051.
4. Montgomery EA, Shuster DD, Burkart AL, Esteban JM, Sgrignoli A, Elwood L, Vaughn DJ, Griffin CA, Epstein JI. Inflammatory myofibroblastic tumours of the urinary tract: a clinicopathologic study of 46 cases, including a malignant example inflammatory fibrosarcoma and a subset associated with high-grade urothelial carcinoma. *Am J Surg Pathol.* 2006; 30: 1502-1512.
5. Harik LR, Merino C, Coindre JM, Amin MB, Pedeutour F, Weiss SW. Pseudosarcomatous myofibroblastic proliferations of the bladder: a clinicopathologic study of 42 cases. *Am J Surg Pathol.* 2006; 30: 787-794.
6. Cook JR, Dehner LP, Collins MH, Ma Z, Morris SW, Coffin CM, Hill DA. Anaplastic lymphoma kinase (ALK) expression in the inflammatory myofibroblastic tumour: a comparative immunohistochemical study. *Am J Surg Pathol.* 2001; 25: 1364-1371
7. Sukov WR, Cheville JC, Carlson AW, Shearer BM, Piatigorsky EJ, Grogg KL, Sebo TJ, Sinnwell JP, Ketterling RP. Utility of ALK-1 protein expression and ALK rearrangements in distinguishing inflammatory myofibroblastic tumour from malignant spindle cell lesions of the urinary bladder. *Mod Pathol.* 2007; 20: 592-603.
8. Tsuzuki T, Magi-Galluzzi C, Epstein JI. ALK-1 expression in inflammatory myofibroblastic tumour of the urinary bladder. *Am J Surg Pathol.* 2004; 28: 1609-1614.
9. Rao RN, Ranjan P, Singla N, Pandey R. Inflammatory myofibroblastic tumour of the urinary bladder diagnosed by anaplastic lymphoma kinase immunostaining. *Urol Ann.* 2012; 4: 115-118.
10. Teoh JY, Chan NH, Cheung HY, Hou SS, Ng CF. Inflammatory myofibroblastic tumours of the urinary bladder: a systematic review. *Urology.* 2014; 84: 503-508.
11. Wei L, Jianbo L, Qiang W, Hai Y, Zhixiang L. Inflammatory myofibroblastic tumour of the bladder: case report and review of the literature. *Can Urol Assoc J.* 2013; 7: e237-e240.
12. Przkola R, Bolder U, Schwarz S, Jauch KW, Spes J, Andreesen A, Mackensen A. Regression of nonresectable inflammatory myofibroblastic tumours after treatment with nonsteroidal anti-inflammatory drugs. *Eur J Clin Invest.* 2004; 34: 320-321.
13. Kim HW, Choi YH, Kang SM, Ku JY, Ahn JH, Kim JM, Chung JM, Ha HK, Chung MK. Malignant inflammatory myofibroblastic tumour of the bladder with rapid progression. *Korean J Urol.* 2012; 53: 657-661.